

*

Approach to building Assessment and Plan

Dr Rahul Gill

APD/HOSPITALIST

07/06/2020

Goal

Building A/P and not Mx of conditions

Case

78 y.o. male with SOB

- symptoms started approximately 1 week ago with “hard time to breathe.” progressively worsened, unable to walk from room to room.
- Fevers +. Daily max 101. reduces with Tylenol x 3 days
- Cough > productive with small amount of yellowish phlegm x 1 week.
- Mild 3-4/10 CP, LL chest more on inspiration, Non exertional

- “cold type symptoms” initially >stuffy nose and sore throat > improved

- denies any nausea vomiting or constipation
- He denies any sick contacts.
- No weight changes or edema or legs

ROS- negative otherwise

Past Medical History:

- DM2
- Atrial fibrillation
- prostate Cancer
- Skin cancer
- Hypertension
- TIA
- CADx 2 stents 10 yrs ago,

Family History

- Father >lung, brain cancer
- Mother > stroke

Allergies- Suplha

Past Surgical History:

- *mohs left upper cheek*
- 12/15 COLONOSCOPY
- SHOULDER ARTHROSCOPY W/ ROTATOR CUFF REPAIR *left*
- prostatectomy
- LHC

Social History

Former Smoker 40PY

Alcohol use: 1 drink/week

Drug use: No

Lives with is wife at home. Worked as lawyer . Retired now. Can take care of his ADLs. He drives. Does not use walker or cane.

Prior to Admission Medications

- aspirin EC 81 mg daily.
- Atorvastatin 40 mg daily
- Metoprolol XL 100 daily
- irbesartan 150 mg tablet daily
- Synthroid 85mcg once daily .
- Zoloft 25mg daily
- Metformin 500 BID
- Glimepride 1 mg daily

Past Medical History:

- DM₂
- Atrial fibrillation
- prostate Cancer
- Skin cancer
- Hypertension
- TIA
- CADx 2 stents 10 yrs ago,

Vital Signs:

BP: 100/58

Resp: 21

SpO₂: 94 on 6l NC

Pulse: 130 irregular

Temp: 97.7 °F (36.5 °C)

Weight: 68 kg (150 lb)

Physical Exam:

- General: in mild respiratory distress due to tachypnea. Laying comfortably in bed on NC
- HEENT: Clear oropharynx, moist MM. No JVD
- Pulmonary: TACHYPNEA. Symmetric chest expansion. Course lung sounds but no wheezing or crackles No CHEST WALL TENDERNESS
- Cardiac: IRR and Fast, normal S₁ and S₂, no murmurs.
- Abdomen: Benign
- Musculoskeletal: no edema
- Neurological: A/Ox₃, no focal deficits, sensation/strength equal bilaterally, cooperative w/ exam.
- Skin: No rashes or lesions.

WBC: 11.63 (H)
RBC: 4.77
HGB: 14.4
HCT: 43.8
MCV: 91.8
MCH: 30.2
MCHC: 32.9
RDW - CV: 11.8
RDW - SD: 40.2
Platelet Count: 500

MPV: 9.9
nRBC, absolute: 0.00
nRBC, percent: 0.0
Neut abs: 10.38 (H)
Lymph abs: 0.66 (L)
Mono abs: 0.57
Eos abs: 0.01
Baso abs: 0.01
Imm Grans abs: 0.10
Neut %: 89.2
Lymph %: 5.7
Mono %: 4.9
Eos %: 0.1
Baso %: 0.1
Imm Grans %: 0.9

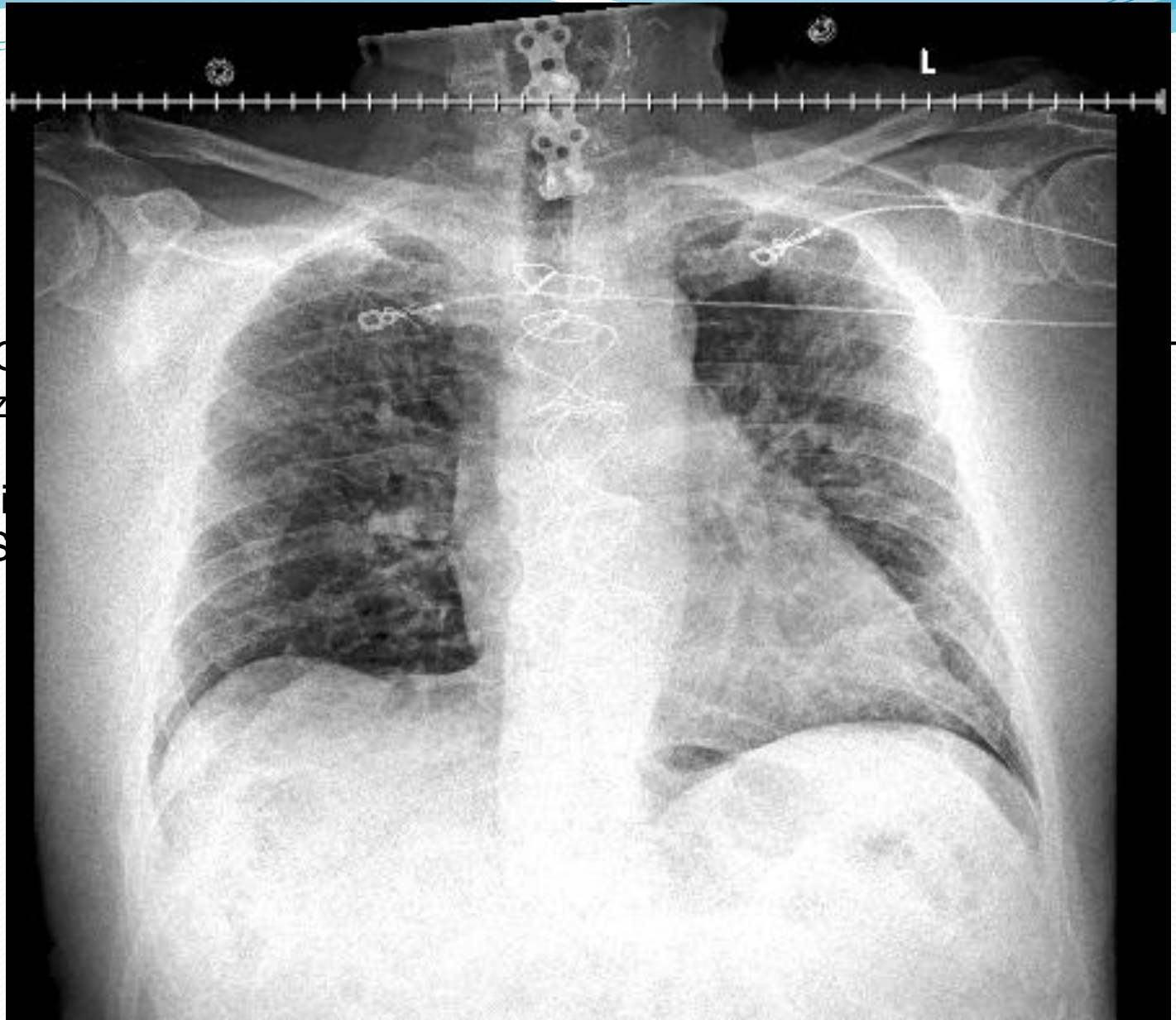
Sodium: 131 (L)
Potassium: 3.2 (L)
Chloride: 98
CO₂: 22
AGap: 11
Glucose: 150 (H)
BUN: 27 (H)
Creatinine: 1.30 (H)
BUN/Creat Ratio: 20.8 (H)
eGFR Non-African Amer.: 57 (L)
eGFR African Amer.: 66
Osmolality calc: 276 (L)
Calcium: 8.2 (L)

Total Protein: 6.4
Albumin: 2.7 (L)
Globulins: *
A/G Ratio: *
Alk Phos: 55 (L)
AST (SGOT): 97 (H)
ALT (SGPT): 82 (H)
Bilirubin, Total: 0.7

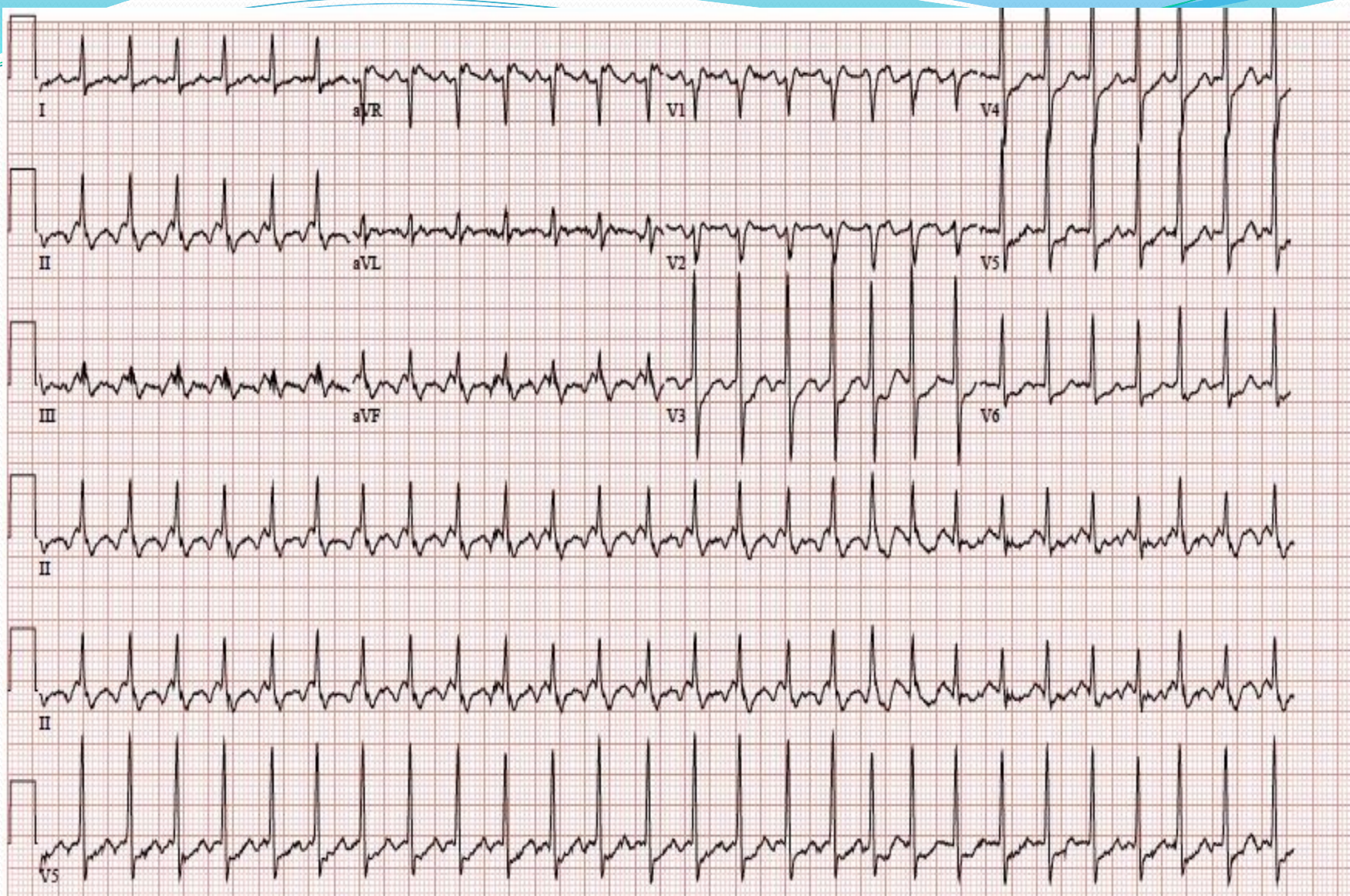
CXR

FINDING
heart size

Impressi
IMPRES



The



Starting point- Perspective Summary

65 y.o. male w has a past medical history of Abdominal cramping, Anxiety, Arthritis, Atrial fibrillation (HCC), Carotid artery occlusion, Chicken pox, Colitis, Coronary artery disease (9/12/13), Depression, Dyslipidemia, Essential hypertension, benign, Fall, Hepatitis, High cholesterol, , Low testosterone, Migraine, Myocardial infarction (HCC) (8/24/2013), Psoriatic arthritis (HCC), Psoriatic arthritis (HCC), Psychiatric problem, who also does not have any history of lupus(HCC), colon cancer(HCC), Crohns(HCC) who presents with

Assessment/Plan:

[REDACTED] male with a past medical history of hypertension, prediabetes, CKD, and osteoarthritis who presents with worsening of prior exertional chest pain x 3days consistent with ACS-NSTEMI s/p aspiration thrombectomy/PCI with DESx3.

65 y.o. male w has a past medical history of Abdominal cramping, Anxiety, Arthritis, Atrial fibrillation (HCC), Carotid artery occlusion, Chicken pox, Colitis, Coronary artery disease (9/12/13), Depression, Dyslipidemia, Essential hypertension, benign, Fall, Hepatitis, High cholesterol, , Low testosterone, Migraine, Myocardial infarction (HCC) (8/24/2013), Psoriatic arthritis (HCC), Psoriatic arthritis (HCC), Psychiatric problem, who also does not have any history of lupus(HCC), colon cancer(HCC), Crohns(HCC) who presents with

65 y.o. male w has a past medical history of Depression/Anxiety, Atrial fibrillation not on AC,, Coronary artery disease s/p stent in 2010 and CABG in 2013, ,hypertension, who presents with worsening SOB for 1 week a/w CP and cough

Problem list-

- Relevant
- Order of priority
- Language to talk to someone and not just a storage with unlimited space

PROBLEM list –

1st problem > Presenting vs most serious
readdressed daily

Diagnosis/Issue

Symptom/Sign > D/D unless clear diagnosis

Likely hood of D/D

Assessment- things that have been done so far. Relevant clinical information (NOT HPI), interpretation of information you have.

Plan- things to do.

- 
- Build a problem list.

D-Dimer Q	<0.2
Procal	0.90
CRP:	7.96 (H)
ESR	95
BNP	102

COVID Positive

Delivery System, POC: NBR Mask
FIO₂, POC: 100
pH ABG POC: 7.43
pCO₂ ABG POC: 30 (L)
pO₂ ABG POC: 87
HCO₃ ABG POC: 20.0 (L)
Base Ex ABG POC: -4 (L)
O₂ Sat ABG POC: 97
A-a Gradient, POC: 588
P/F Ratio POC: 87
a/A Ratio, POC: 0.13
tCO₂ ABG POC: 21 (L)
Site, POC: L Radial

DAY 7 – recurrence of Fever and/or leukocytosis
Expected vs unexpected.

Line infection vs superficial thrombophlebitis

PNA

UTI

Cdiff

DVT

Meds